

## Partners in Practice

- ▶ **Cerebrospinal Fluid Preservation**  
for Cytological Evaluation
- ▶ **What is your diagnosis?**
- ▶ **New Tests available and**  
**Ionised Calcium testing requirements**
- ▶ **Meet the Vetnostics Pathologists**



## Welcome...

Welcome to the *NEW Vetnostics Newsletter* which we hope you find interesting and topical. The intention is to provide information with regard to new tests/assays and advice with regard to diagnostic testing and sampling. Furthermore, the section 'What is your diagnosis?' will be based upon interesting cases we have seen in the preceding months. Feedback is always appreciated so please let us know if there are any topics you would be interested to see in future newsletters. In this regard, please feel free to contact Dr Doug Hayward on 02 9005 7272 or by email: [doug.hayward@vetnostics.com.au](mailto:doug.hayward@vetnostics.com.au).

# Cerebrospinal Fluid Preservation for Cytological Evaluation

## Dr Doug Hayward - Veterinary Clinical Pathologist

Diagnosis of neurological disease in small animal practice can be challenging given the limited availability of advanced diagnostic imaging techniques and the time-consuming and often cost-prohibitive nature of a thorough work-up. In addition to routine serum biochemistry and haematology, further initial work-up may include urinalysis, coagulation time assessment, dynamic bile acids, serology (including infectious agents), radiography (typically of limited value) and Cerebrospinal fluid (CSF) analysis.

CSF analysis is an integral component of the work-up of central nervous system disease where the cause of the clinical signs is not obvious (e.g. trauma) and where not contraindicated. Despite the fact that CNS analysis frequently does not provide a definitive diagnosis, the value often lies in identifying the presence or absence of abnormal features and in establishing differential diagnoses (Chrisman, 1992).

The method of CSF collection, contraindications and interpretation of findings are beyond the scope of this article which instead will focus upon the various methods of preserving the sample once collected until analysis at the laboratory. Particularly where fluid total protein is low (observed in 'normal'

fluid and that which is mildly altered), cells lyse rapidly and cell counts/cytological evaluation of unpreserved fluid is ideally recommended to be performed within 30-60 minutes of collection (Fry et al., 2006). Where a delay in processing is likely, various recommendations have been put forward with regard to allowing an accurate differential cell count and enhancing morphologic evaluation such as those described below:

- Fry et al. (2006) have advised the addition of foetal calf serum (20% concentration)
- Bienzle et al. (2000) recommend the use of autologous serum (11% concentration).
- An alternative approach reported to produce good results if performed correctly is the addition of 2 drops of 10% buffered formalin for each 1ml of CSF (Carmichael, pers. comm.).
- Where CSF volume is low (<0.5ml in total), hydroxyethyl starch (Hetastarch) can be added to the sample for all routine assays (1:1) although the dilutional effect will need to be taken into account when calculating results (De Lorenzi and Mandara, 2010).

## At Vetnostics we recommend the following handling procedures for CSF collections:

- where sufficient CSF is harvested, dividing the fluid into 2 aliquots; one unadulterated specimen is provided in a sterile container for microbiology and/or serology whilst the other CSF aliquot is placed in a small EDTA tube (1/2 to 1ml – ring lab for supplies if required) for total nucleated cell count, protein measurement and cytological evaluation. Carmichael (1998) states that protein and enzyme concentrations in CSF are relatively stable. Consequently, submission to the laboratory by routine methods (delivery, post or courier) is not expected to significantly alter these results (Figure 1).
- in our experience, submission of CSF in EDTA has not typically been associated with poor preservation where CSF samples are likely to reach the laboratory in a relatively short period of time.

With regard to the sample assigned for cytological examination:

- Although potentially more time-consuming, the preparation at the practice of sedimentation slides and submission to the laboratory for staining and cytological evaluation (multiple described techniques) has been advocated.

Utilising one of the above described options should help to maximise diagnostic cytological information obtained from CSF analysis.

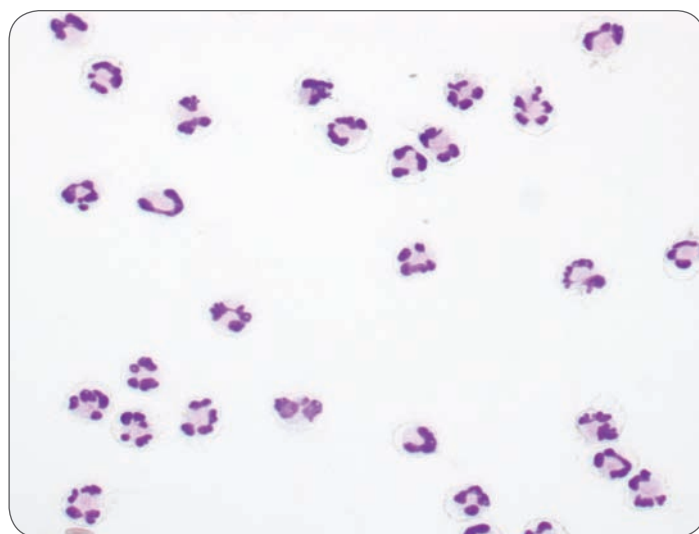

Figure 1: CSF sample from a camel illustrating excellent cell preservation (Diff-Quick stain, x40). CSF sample was collected into an EDTA tube at the country practice and slide was prepared shortly after receipt of the specimen in the laboratory.



## References

1. Bienzle D, McDonnell JJ, Stanton JB. Analysis of cerebrospinal fluid from dogs and cats after 24 and 48 hours of storage. *J Am Vet Med Assoc.* 2000;216:1761-1764.
2. Carmichael N: Nervous system. In Davidson M, Else R, Lumsden J (eds): *Manual of small animal clinical pathology*, Cheltenham, UK, British Small Animal Veterinary Association, 1998, pp 235-240.
3. Chrisman CL. Cerebrospinal fluid analysis. *Vet Clin North Am Small Anim Pract.* 1992;22:781-810.
4. De Lorenzi D, Mandara MT: The Central Nervous System. In Raskin RE, Meyer DJ (eds): *Canine and Feline Cytology: A color atlas and interpretation guide*, ed 2, St. Louis, Saunders Elsevier, 2010, pp 325-365.
5. Fry MM, Vernau W, Kass PH, Vernau KM. Effects of time, initial composition, and stabilizing agents on the results of canine cerebrospinal fluid analysis. *Vet Clin Pathol.* 2006;35:72-77.

# What is your diagnosis?

What are the intracytoplasmic granules identified within the neutrophils?

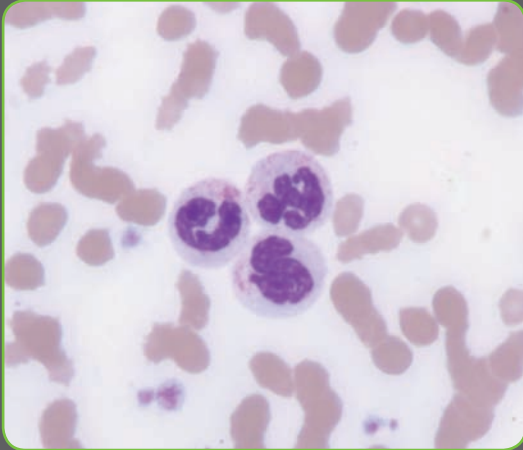


Figure 2:  
Three neutrophils with intracytoplasmic granules  
(Wrights stain, x100)

Blood smear (Wright's stain) from a 13 year old neutered female Birman cat presented with vomiting of a few days duration, weight loss, severe jaundice and lethargy. Full blood count results were unremarkable apart from a mild neutrophilia (no left shift) and lymphopenia. Serum biochemistry revealed a moderate cholangiohepatopathy and moderate to marked increase in total bilirubin.

## New sampling requirements for ionised calcium

For ionised calcium testing, we now recommend:

- 1) Blood samples (of at least 2.5-5 mls whole blood) should be collected into a non-anticoagulant (plain red top) vacutainer tubes (may need to order from our stores department: material number 654171)
- 2) The sample should then be centrifuged and the serum (minimum volume required for test is  $\frac{3}{4}$  ml of serum but a greater volume is preferred) removed anaerobically (using an evacuated needle and syringe through the tube cap) and placed into a second non-anticoagulant plain red top vacutainer tube (once again, inserting the needle through the cap of the tube).
- 3) The tubes should not be uncapped under any circumstances.
- 4) Keep the serum cool at all times.
- 5) Analysis should be performed within 48 hours after collection for optimal results.
- 6) **Alternatively the serum can be frozen, shipped on dry ice, and analyzed within seven days**

The cost of this assay is \$60.00 excluding GST (request ionised calcium under other tests). Please advise one of the veterinary pathologists when submitting to ensure appropriate handling.

# Answer...

The neutrophils revealed low to moderate numbers of fine eosinophilic-stained intracytoplasmic granules. Considerations include:

- toxic granulation,
- mucopolysaccharidosis,
- Birman Cat Neutrophil Granulation Anomaly.

The granules were too fine, regular in size and eosinophilic for toxic granulation and they did not stain with toluidine blue or alcian blue (expected with mucopolysaccharidosis). They were therefore most likely considered to reflect Birman Cat Neutrophil Granulation Anomaly. This is a cytoplasmic granule alteration in neutrophils inherited as an autosomal recessive trait in Birman cats and is considered to be an incidental finding with affected cats not being predisposed to infections (Hirsh and Cunningham, 1984).

*Hirsh VM, Cunningham TA. Hereditary anomaly of neutrophil granulation in Birman cats. Am J Vet Res 1984;45:2170-2174*

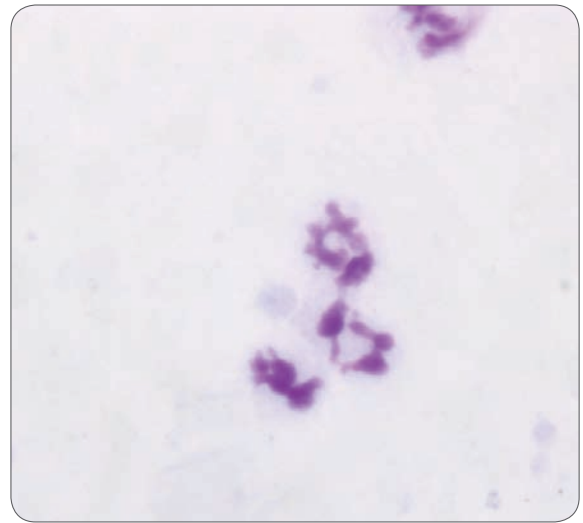


Figure 3: Neutrophils from same case as in figure 2 (Toluidine Blue stain, x100)

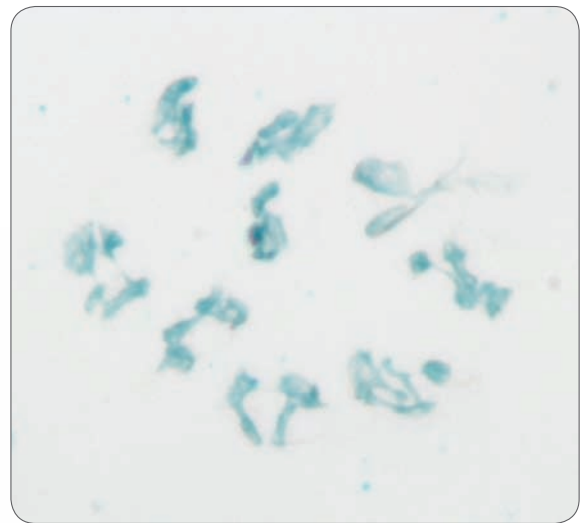


Figure 4: Neutrophils from same case as figures 2 and 3 (Alcian Blue stain, x100)

# NEW TESTS Available at Vetnostics

## 1 T & B CELL IMMUNOCYTOCHEMISTRY IS NOW AVAILABLE ON CYTOLOGY SMEARS OF LYMPHOMA CASES:

For Lymphoma cases diagnosed by cytological examination of fine needle aspirates (FNA), we can now perform immunocytochemistry on both stained and unstained smears of these FNA aspirates and determine T or B-cell phenotype when requested.

Cost of T&B immunocytochemistry on submitted smears is \$70 (excluding GST).

Turnaround time for this test is 3-5 working days.

For T/B cell immunocytochemistry on FNA aspirates we require:

- 1) A minimum of 4 well made cytology smears
- 2) Smears can be submitted stained (with Diff-Quik) or unstained.
- 3) Smears must contain a significant number of intact lymphoid cells forming a monolayer for immunocytochemistry to succeed
- 4) Smears must not have immersion oil placed on them
- 5) Smears must be made on frosted edge glass slides labelled with patient details

## 2 FLOW CYTOMETRY:

Flow cytometry involves staining live cells with labeled antibodies that bind to proteins expressed on the cell surface. Different types of lymphocytes express different protein (for example T cells express the protein CD3, and B cells express the protein CD21). The cells are analyzed on a flow cytometer, which

tells us how many cells of each type are present. This information allows us to determine the lineage of the cells present, and whether they are homogeneous (more consistent with neoplasia) or heterogeneous (more consistent with a reactive process).

Flow cytometry is recommended for the following indications:

PRESENTING COMPLAINT	BEST SITE	BEST TEST	COST TO SUBMITTERS (EXCL GST) (AS STANDALONE TESTS)	TURNAROUND TIME	FOR COLLECTION REQUIREMENTS AND SPECIAL FORMS
Lymphocytosis or Leukaemia	Peripheral Blood	Flow cytometry	\$240 (includes FBC)	7-10 working days	Ring Vet Pathologist
Lymphocyte rich effusion	Effusion Fluid	Flow cytometry	\$200	7-10 working days	Ring Vet Pathologist

## 3 PARR (PCR for antigen receptor rearrangements):

The PARR assay is a PCR assay in which we are amplifying DNA. The results tell us if the majority of cells in the sample are derived from the same original clone (most consistent with neoplasia), or from multiple clones (most consistent with a reactive process).

The PARR assay can be used in the following situations:

PRESENTING COMPLAINT	BEST SITE	BEST TEST	COST TO SUBMITTERS (EXCL GST) (AS STANDALONE TESTS)	TURNAROUND TIME	FOR COLLECTION REQUIREMENTS & SPECIAL FORMS
Lymphoma suspect, equivocal histopathology/cytology	Lymph node	PARR	\$200	7-10 working days	Ring Vet Pathologist
Rare suspicious cells in peripheral blood, no Lymphocytosis	Peripheral Blood	PARR	\$200	7-10 working days	Ring Vet Pathologist
Splenomegaly, equivocal histopathology/cytology	Spleen	PARR	\$200	7-10 working days	Ring Vet Pathologist
Peripheral cytopaenia, suspicious cells in marrow	Bone Marrow	PARR	\$200	7-10 working days	Ring Vet Pathologist
Lymphocyte rich CSF	CSF	PARR	\$200	7-10 working days	Ring Vet Pathologist

For further details regarding these tests and collection requirements please contact:  
Dr George Reppas (02 9005 7012) or Dr Doug Hayward (02 9005 7272).

# Farewell...

## David Snow

As some of you may be aware, David has decided to leave Vetnostics after 21 years of service to the company. David joined Vetnostics in 1990 when we were part of Macquarie pathology and, after a period, assumed control of the direction of Vetnostics. In this role, David exhibited passion and commitment to the ongoing success of Vetnostics and presided over a continual expansion of the practice.

David has experienced mixed emotions in arriving at this decision, but has decided to start new ventures that he has been looking forward to for some time. Examples of this include volunteer activity with various organizations such as packing books for the Indigenous Literacy Foundation and expanding his activities with the Delta Society ([www.deltasociety.com.au](http://www.deltasociety.com.au)) for which Vetnostics has for many years been a key supporter (another David initiative).

David will try to develop a specific program for Pet Therapy teams to visit dementia patients in aged care facilities. At a personal level, David will be pursuing his physical (gym work, kayaking, skiing) and mental (bridge, reading – high brow stuff only) activities, as well as overseeing the building of his new house.

Many will miss David as he had developed close relationships with staff (at all levels) as well as clients. For anyone wishing to contact David he can be reached by email at: [david.snow@optusnet.com.au](mailto:david.snow@optusnet.com.au)

David's parting comment was:

***"Now as I have often said, it is time for me to smell the roses whilst they are around me, not over me."***

The Vetnostics team wish David all the best in his future pursuits which no doubt will be attacked with the vigour for which he is renowned.

---

## Submission form for exotics and small mammals

Please note that there is a dedicated submission form available for exotics (reptiles, birds, etc.) and small mammals (rabbits, ferrets, rats, mice, etc.). If you deal with such animals and require this form, please contact Kristen Todhunter:

email [kristen.todhunter@vetnostics.com.au](mailto:kristen.todhunter@vetnostics.com.au)  
or phone (02 4923 4234)



---

## New Complete Profile for dogs and cats



In addition to the many other changes on the recent Price List released in March of this year, we have put together a Complete Profile for both cats and dogs. Please note that in addition to FBC, biochemistry and further tests as appropriate for the species, standard urinalysis is included in this new profile for both dogs and cats and concurrent submission of a urine sample is requested. Many thanks.

## Meet our Veterinary Pathologists



**DR BRUCE C. DUFF**

*BVSc, Dip VetPath, MCom, AFAIM (Clinical Pathologist)*




**DR ANGELA BEGG**

*BVSc, Dip VetPath, PhD (General Pathologist)*




**DR DAVID TAYLOR**

*BVSc, Dip ACVP (Histopathologist)*



**DR GEORGE REPPAS**

*BVSc, Dip VetPath, FRCVSC, Dipl. ECVP (General Pathologist)*




**DR DOUG HAYWARD**

*BSc, BVSc, MRCVS, FRC Path (Clinical Pathologist)*



**DR KRISTEN TODHUNTER**

*BS, DVM, MACVSc (General Pathologist)*



**DR BRETT STONE**

*BVSc (Hons), BBiomedSc (Hons), MACVSc (General Pathologist)*



**DR MICHELLE DENNIS**

*DVM, PhD, Dip ACVP (General Pathologist)*